

Development of focal melanised lesions in muscle tissue of farmed Atlantic salmon

Håvard Bjørgen¹, Randi Haldorsen², Odd Medhus², Øyvind Oaland², Øystein Wessel¹, Espen Rimstad¹ and Erling Olaf Koppang^{1*}

¹Faculty of Veterinary Medicine, Norwegian University of Life Sciences, Ullevålsveien 72, Box 8146 Dep., Oslo, Norway

²Marine Harvest ASA, Sandviksbodene 77AB, 5035 Bergen, Norway

Introduction

In ectothermic vertebrates, melanin production may occur in subpopulations of leucocytes. These cells, called melano-macrophages in fish, are abundant in lymphoid organs and also at sites of inflammation. The function of melanin production in melano-macrophages is unknown.

Pigmented muscle lesions are common in farmed Atlantic salmon with an average of 20% affected individuals at slaughter in Norway. The current hypothesis is that such changes initiate as haemorrhages (focal red changes) which develop into focal melanised changes. Histologically, focal melanised changes are characterized as sites with chronic inflammation with abundant presence of melano-macrophages. Recently, the development of chronic inflammatory lesions were associated with the presence of *Piscine orthoreovirus* (PRV). In this study, we followed the development of focal red and melanised changes in a population of farmed salmon during the sea water phase. The aim of the study was to reveal novel characteristics in the development of focal melanised changes.

Methods

During a one-year period, seven samplings, each including 600 individuals, were investigated. Samples were collected from 2 different sea cages each time. All fillets were screened macroscopically for pathological changes. The occurrence of muscle changes were registered and samples were subjected to histological examination and transcriptional and immunohistochemical analysis for PRV infection. PCR analysis for PRV detection was performed on 60 individuals after each sampling.

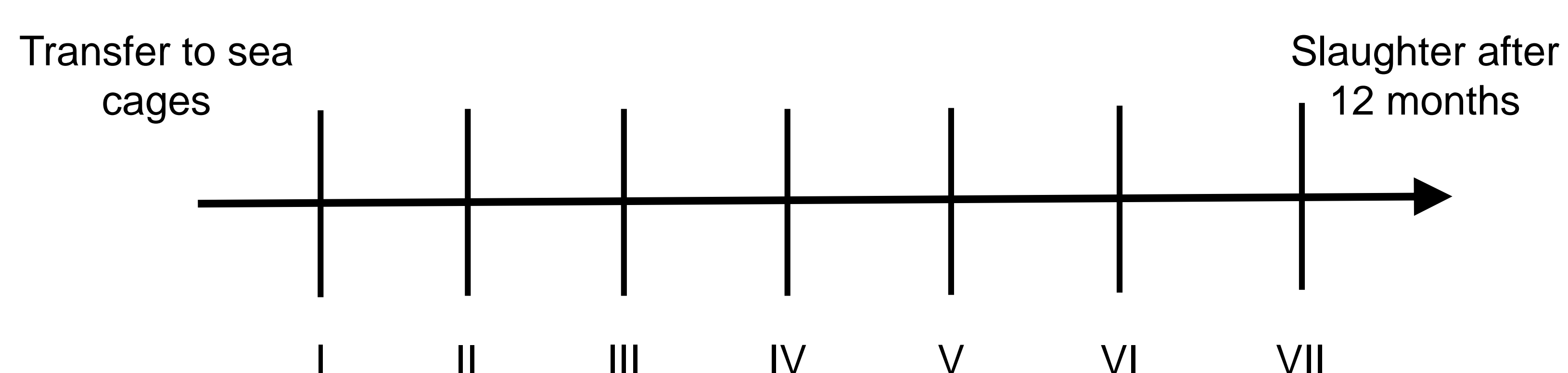


Fig. 1. Experiment outline. Large scale samplings were performed at seven different time points during the sea water phase.

Results

PCR analysis for PRV was negative for all fish in the 3 first samplings. At the fourth sampling, 10 % were positive. At the fifth sampling, 67 % were positive. At the last two samplings, the entire population was infected.

In the first three samplings, the prevalence of melanised focal changes was low. The observed changes were of a less severe character than those collected from virus-positive fish later in the experiment. Histological differences were also revealed, as the degree of tissue damage and inflammation was low in the virus-negative fish. The myocytes were mostly intact, while some infiltrating melano-macrophages were present between the myocytes. In the virus-positive fish, the changes were generally of a more severe character, and the histological picture was dominated by a granulomatous inflammation and a vast necrosis of myocytes. PRV antigen was detected in such changes.

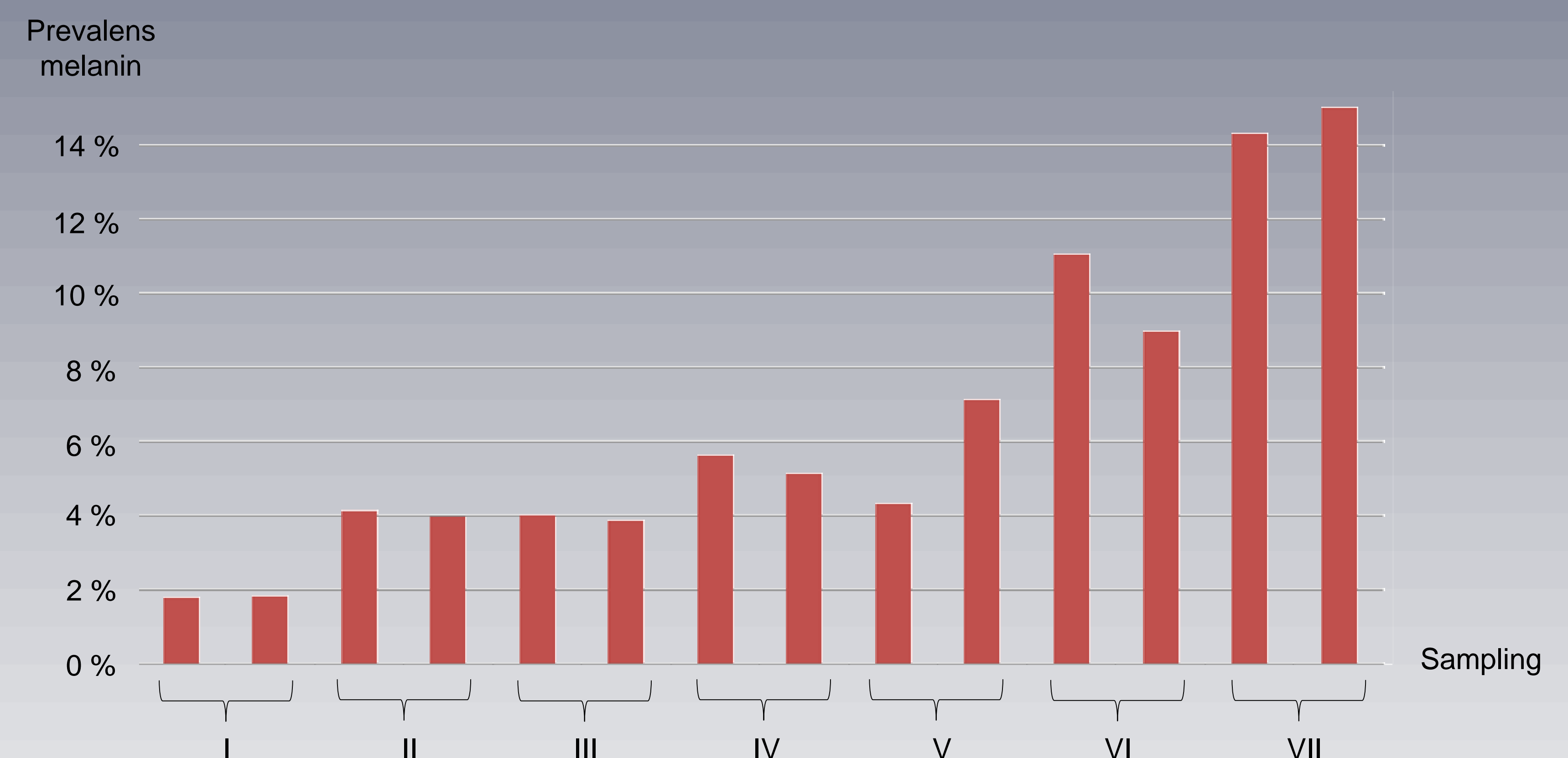


Fig. 2. Prevalens of focal melanised changes at different samplings. The two bars in each sampling represent different sea cages.

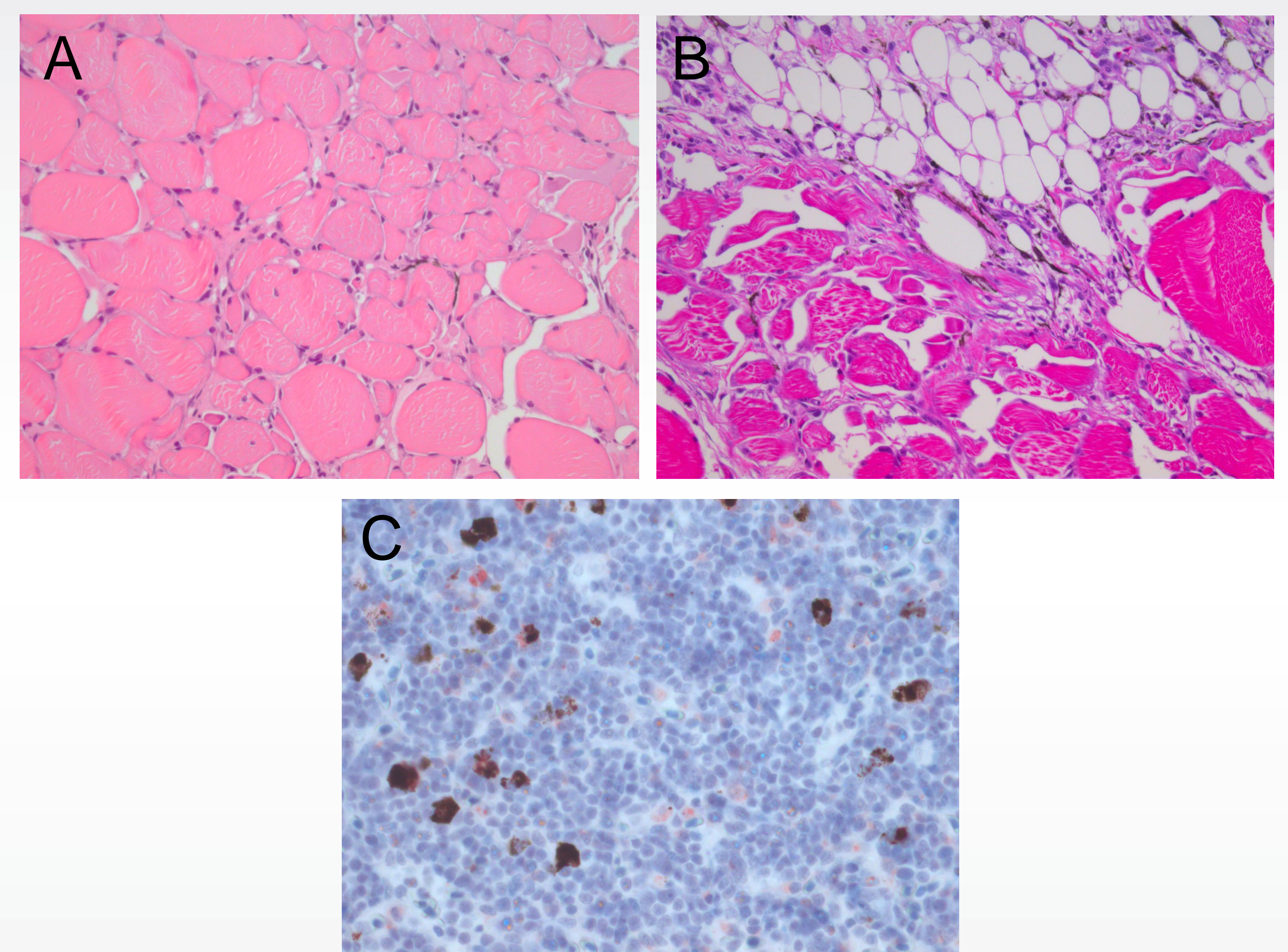


Fig. 3. Histological investigations from fish at different infectious stages. A) A melanised focal change in a virus-negative fish. Melano-macrophages are present between seemingly non-affected myocytes. B) A melanised focal change in a virus-positive fish. Abundant amounts of inflammatory cells and melano-macrophages in the affected tissue. C) PRV-positive cells in the spleen. Some of the melano-macrophages display positive staining (red) (Immunohistochemistry targeting membrane protein Zigma1, PRV).

Conclusions

- We have shown the development of a PRV infection in a normal, field case scenario. In addition, the occurrence of focal melanised changes was registered and an increasing prevalence during the sample period was registered.
- We have revealed that focal melanised changes do occur in the fish prior to detection of PRV infection. However, the histological appearance of such changes differed from those in virus infected fish, with presence of melano-macrophages dispersed between seemingly non-affected myocytes, as opposed to severe granulomatous changes when virus is present.
- The results show that there are different manifestations of melanisation. More severe histological and macroscopical changes can be detected when virus is present.



Norwegian University of Life Sciences